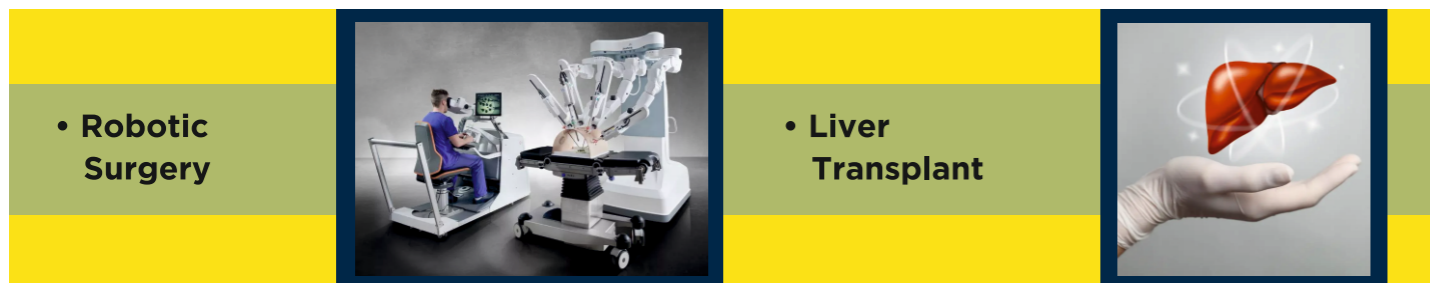


Tech in Healthcare Vision Forward



• Robotic Surgery

• Liver Transplant

Dr. CH Care

Health Tips

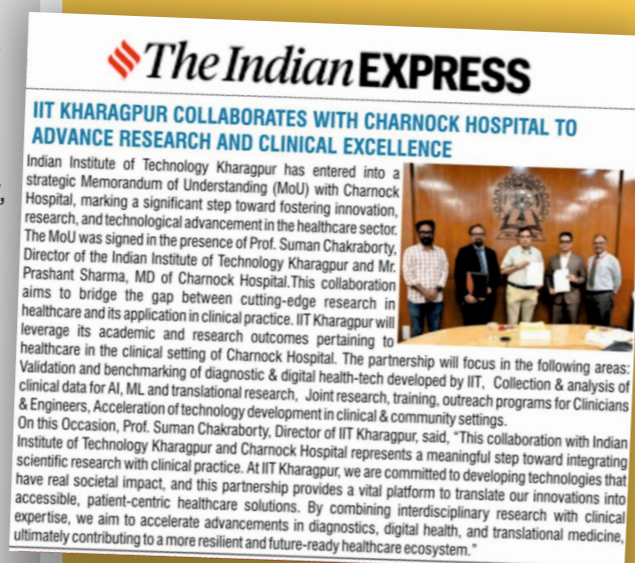A mixture of Haldi (*turmeric*), cinnamon powder, grated ginger and a cup of lukewarm water offers potent anti-inflammatory antioxidant and digestive benefits.



This combination can boost immunity, support weight management by aiding metabolism, reduce joint pain and improve heart health. Best consumed early in the morning on an empty stomach.

Note: Patients with kidney stone, gallbladder stone or patients on blood thinner medication should consult their doctors as high dose of turmeric can cause side effects.

Success Stories



• 15K+ Successful Cardiac procedures

• 700+ Successful Cardiac cases every month

For suggestions and queries, please write to: info@charnockhospital.com



Charnock
HOSPITALS

BMC 195, Teghoria, Biswa Bangla Sarani, Kolkata 700 157, West Bengal, India

24x7 Emergency Helpline: 033 40 500 500

www.charnockhospital.com



THE MEDICAL PULSE

DREAM BIG, ACHIEVE BIG

A Newsletter of Charnock Hospitals



Editorial Desk

Dr Mita Mazumdar
Medical Superintendent - I,
Charnock Hospital

Dear All,

It gives me immense pleasure in announcing the launch of "**Medical Newsletter (The Medical Pulse)**" from the Desk of **Medical Administration Charnock Hospitals**.

Living in a world in recent times inundated with relentless volume of social media, emails, messages, and other platforms, staying connected irrespective of the route dismantling all odds, weathering all storms with calm efficiency, surging forward, converting all long drives into an epic journey has always been the driving force of every offshoot branching from the big tree called "**CHARNOCK HOSPITALS**".

Fundamentally remaining strong, our endeavour will always be to create a conclave via this newsletter converging all unique cases, with a "Case of the Month" commanding attention. Staff and hospital achievements and recognition, updates on technical advancements, health tips will be our area of focus.

Soliciting unwavering support from everyone.

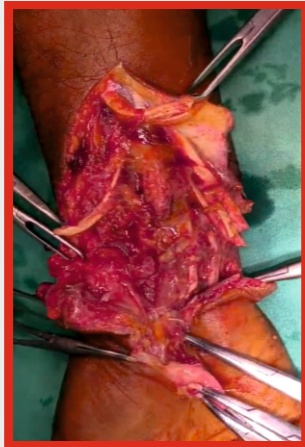
Inside Charnock

News Corner

A middle aged man came to Charnock Emergency with shoulder dislocation and a cut injury at wrist when a sharp tin sheet hit him on the right hand during a storm.

He was initially seen by the Orthopedic Surgeon Dr Rajan Lohia who consulted Dr Arnab Mondal, Plastic Surgeon for the laceration at wrist.

Prompt response taken at emergency and patient was put to Operation Theatre within half hour of initial presentation. On exploring the wrist injury under tourniquet control it was found that all structures in front of wrist practically severed.



The radial and ulnar artery was cut, so as median nerve, FCR, FCU, FPL tendon, all 4 FDS and FDP of index finger

We repaired the nerve, all the tendons and the ulnar artery was anastomosed.

The ortho team then put a K Wire for the radial styloid fracture and screws for the shoulder dislocation.

The hand improved, circulation re-established, hand color and temperature became normal.

The patient went home after 2 days with good recovery and is under follow up.

Overall, it was an excellent team effort, thanks to the Plastic Surgery team led by Dr Arnab Mondal, Ortho team led by Dr Rajan Lohia, the ER team, the ward and OT staffs and Anaesthetist Dr Mrinal Mallick.

Timely Recognition Saves a Life:

Acute Cardiac Arrhythmia

A middle-aged patient presented with progressive breathlessness, cough, and pedal edema over 2-3 days.

ECG revealed wide complex tachycardia, with a background of ischemic heart disease (post-CABG) and hypertension. The patient was hemodynamically unstable on arrival.

During monitoring, the patient developed unstable tachycardia (~170 bpm).

Immediate DC cardioversion was performed, successfully restoring sinus rhythm and preventing further deterioration.

Further evaluation showed reduced left ventricular ejection fraction (31%), indicating significant cardiac compromise.

The patient was managed with a protocol-based approach, including amiodarone infusion, optimized heart failure therapy, antiplatelets, statins, and intensive monitoring in the ICU, along with supportive care.

Outcome: The patient stabilized with timely intervention.

Key Insight: Early recognition, rapid cardioversion, and coordinated cardiac care are crucial in managing life-threatening arrhythmias.

ADVERTISEMENT BLOCK

Stick to right choice

Get checked with the Knee Replacement Specialist today

TREATMENTS

- TKR • THR • Arthroscopy
- Paediatric Orthopaedics • Trauma care

• Highly Experienced Orthopaedics Team • World class Service
• Affordable Cost • Laminar air flow supported Modular OT's
• High-End C-Arm

Call Now
85848 30801

www.charnockhospital.com

Patient First

Spot Light

Case of the month

A baby born at just 26 weeks 4 days of gestational age by emergency cesarean section (*mother started leaking P/V*). Birth weight only 820 gm. Baby did not cry at birth, there was no spontaneous breathing, severe bradycardia.

Baby was resuscitated and intubated at OT, shifted to NICU, put on mechanical ventilation.

For next 2 weeks baby had undergone stormy course.

1. Severe respiratory distress (*Managed with surfactant*)

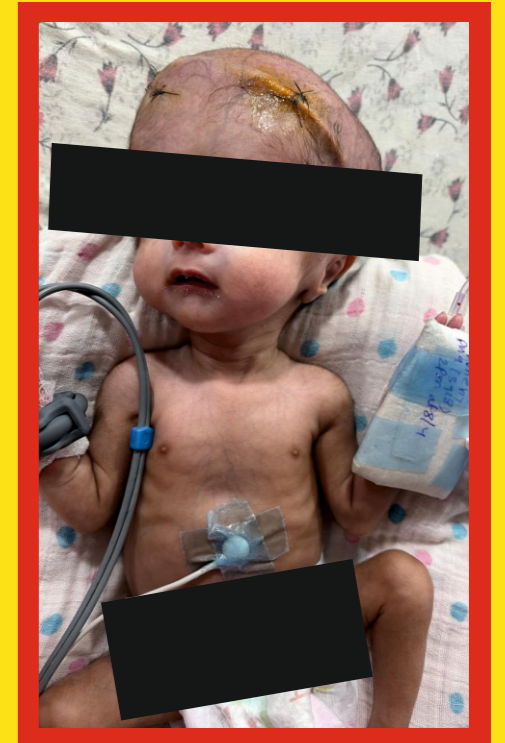2. Severe hyperkalemia (*K 9.4, managed with insulin glucose infusion, Inj calcium gluconate*)

3. Symptomatic hypercalcemia (*Sr Ca 6.2*)

4. Severe sepsis (*Klebsiella pneumonia*)-managed with antibiotics.

5. Grade IV intraventricular hemorrhage. (*Managed with VSG shunt, for communicating hydrocephalus*).

Now baby thriving well, on Full feed, gaining weight.



Success Stories

Staff & Hospital Achievement

A combined effort pertaining to the above case worth applauding by our team of doctors, nursing officers, technicians, housekeeping staff, and goes without saying the courage exhibited by the parents of the new born who were in consonance with the idea of the new born under taking a major surgery fraught with risk has yielded gratifying result which remains unparalleled, with the new born doing well so far.

Consultants/Doctors

Dr. Prateep Paul
Dr. Srinanda Majumder
Dr. Akash Ray
Sr. Sandeepan sen
Dr. Sunil G
Dr. Runa
Dr. Shisendhu dutta
Dr. Sanjeevan saha
Dr Lopamudra misha

Nursing Staff:

Sister Sheeja
Piyali Chatterjee
Rumpa Ghoral
Monalisa Parvin
Somadrita Sana
Puja Barman

MT

Deeparati Ghosh
Rajdeep Gope
Manisha Hore
Rajeswar maity
Soumen samoi

House Keeping

Kukku Das
Rejina Khatun